

SPINAL CORD SECTIONS

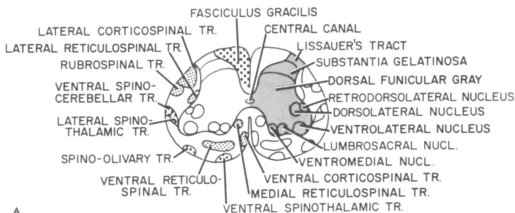
LEVEL: SACRAL II

Sacral levels can be identified by the large amount of gray matter in comparison to white matter.

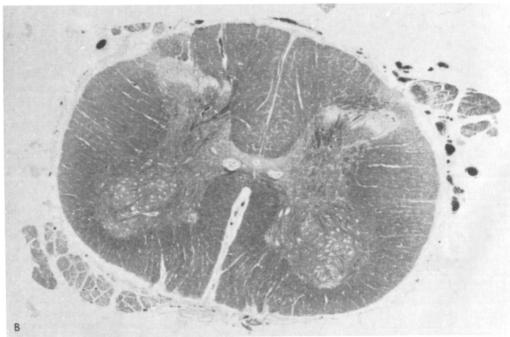
Gray Matter. In this section there are two horns: one sensory (dorsal) and one motor (ventral). In the ventral horn the

retrodorsal, dorsolateral, and ventrolateral nuclei innervate the inferior extremity.

White Matter. Most of the fibers from descending tracts have ended and the bulk of the white matter consists of ascending axons and intersegmental fibers. The dorsal columns at this level contain only fibers from regions innervated by the sacral cord; these form the fasciculus gracilis.



A



B